Cytomorphological evaluation of bone marrow aspirate smears fixed with graded honey at a tertiary hospital in Kenya

Kennedy Oyamo[1]
Susan Tuvei[2]
Tyrus Omondi[2]

[1]oyamo36@gmail.com (+254 721 468 994)

1. Moi University/Academic Model Providing Access to Healthcare (AMPATH) Reference Laboratory, Uasin Gishu County, Kenya.
2. Department of Medical Laboratory Science, Masinde Muliro University of Science and Technology, Kenya

https://doi.org/10.51867/scimundi.6.2.44

ABSTRACT

Bone marrow aspirate cytology depends on preservation of nuclear and cytoplasmic features for microscopic assessment. Honey has been investigated as a naturally derived fixative, but evidence for bone marrow aspirate smears and for the effect of honey concentration is limited. Objective: To evaluate cytomorphological characteristics of bone marrow aspirate smears fixed using 50%, 70%, and 100% honey. Methods: A laboratory-based comparative experimental study was conducted at the Histopathology Laboratory of Moi Teaching and Referral Hospital/AMPATH, Eldoret, Kenya. The final analytical dataset comprised 99 routine diagnostic specimens. Additional smears were fixed with 50%, 70%, or 100% honey and stained using May–Grünwald–Giemsa. Two blinded pathologists independently assessed five domains on a 0–4 scale. Results: Mean overall scores were 2.3 (SD 0.48), 2.1 (SD 0.52), and 1.9 (SD 0.59) for 100%, 70%, and 50% honey, respectively. The highest domain scores were observed with 100% honey and the lowest with 50% honey. Reported nuclear adequacy was 83.8%, 78.8%, and 72.7%, respectively. Conclusion: The results show a descriptive concentration-associated trend, with undiluted honey receiving the highest ratings among the preparations evaluated. Scores were moderate and variable; the results do not establish diagnostic equivalence or suitability for routine use. Further studies should validate standardized honey preparations against a conventional fixative using adequately powered, preferably multi-centre designs, explicit adequacy criteria, and measures of interobserver agreement and diagnostic performance. Until then, honey should not be assumed to replace conventional fixation in routine diagnosis.

Keywords: Bone Marrow Aspirate; Cytomorphology; Fixation; Honey Fixative; Kenya, May–Grünwald–Giemsa

I. INTRODUCTION

Bone marrow aspirate cytology is an important component of the investigation of haematological disorders. Its diagnostic value depends on aspirate quality, smear preparation, fixation, staining, and microscopic interpretation. Adequate fixation helps preserve the cellular features used to recognize haematopoietic populations and their maturation patterns. Distortion of nuclear contours, chromatin, cytoplasm, or background can make morphological interpretation difficult (Gajendra et al., 2015; Lee et al., 2008). Alcohol-based fixatives, including methanol, are used for cytological smears because they preserve cellular detail and are compatible with Romanowsky-type stains. Methanol is volatile and flammable and can be hazardous through inhalation, ingestion, or skin exposure; safe handling requires suitable storage, ventilation, and protective equipment (World Health Organization [WHO], 1997). These considerations have motivated investigation of alternative fixatives that may be accessible and easier to handle in some laboratory settings.

Honey has been investigated as a potential natural fixative in histology and cytology. Its concentrated sugars, acidity, and other physicochemical properties have been proposed as contributing to preservation. Studies have evaluated honey in oral smears, fine-needle aspiration specimens, body fluids, cervical smears, and tissue sections, with results varying by specimen type, concentration, stain, and scoring method (Alwahaibi et al., 2023; Ishaq et al., 2017; Lalwani et al., 2015; Priyadarshi et al., 2022; Sabarinath et al., 2014; Singh et al., 2015). These findings cannot be generalized to bone marrow aspirate smears, where nuclear detail and maturation features are central to interpretation. Evidence on graded honey concentrations for bone marrow aspirate cytology remains limited. This study therefore evaluated the cytomorphological characteristics of bone marrow aspirate smears fixed with 50%, 70%, and 100% honey at a tertiary hospital in Eldoret, Kenya.

1.1 Statement of the Problem

Reliable bone marrow aspirate interpretation depends on preservation of cellular morphology. Nuclear chromatin, nuclear contours, cytoplasmic characteristics, and maturation features support identification of

© 2026 Author(s). This article is licensed under the Creative Commons Attribution–NonCommercial 4.0 International License (CC BY-NC 4.0)

haematopoietic cells; fixation or staining artefacts can compromise these assessments. International guidance describes fresh absolute methanol fixation followed by a Romanowsky stain such as May–Grünwald–Giemsa or Wright–Giemsa for marrow aspirate smears (Lee et al., 2008). Alcohol-based fixatives are established laboratory materials, but their handling requires appropriate storage and safety controls. This has encouraged investigation of alternative fixatives, including honey.

Honey fixation research has reported potentially useful results in oral cytology, fine-needle aspiration, body fluids, cervical smears, and tissue sections (Lalwani et al., 2015; Priyadarshi et al., 2022; Singh et al., 2015). However, these studies used different specimen types, honey concentrations, stains, comparison fixatives, and assessment criteria. Findings from epithelial or tissue preparations cannot establish that honey preserves the subtle maturation and lineage features needed in bone marrow cytology. The available literature also does not establish which honey concentration, if any, is appropriate for marrow smears.

The practical and knowledge gap addressed here is the lack of locally generated comparative evidence on graded honey concentrations for bone marrow aspirate smear morphology in the study laboratory. Without such evidence, a concentration-associated difference in nuclear detail, cytoplasmic detail, cell morphology, staining quality, or background clarity cannot be described for this specimen type and setting. This study therefore assessed those domains in smears fixed with 50%, 70%, and 100% honey. It provides preliminary descriptive evidence; because the reported analysis does not compare honey with a conventional reference fixative or test diagnostic agreement, it cannot establish replacement suitability.

1.2 Research Objective

To evaluate nuclear detail, cytoplasmic detail, cell morphology, staining quality, background clarity, and overall cytomorphological scores in bone marrow aspirate smears fixed with 50%, 70%, and 100% honey.

II. LITERATURE REVIEW

2.1 Theoretical Review

Fixation aims to preserve cellular structures close to their state at collection and to support subsequent staining and microscopic examination. Fixation conditions can affect morphology and downstream staining, so performance must be evaluated for the intended specimen and diagnostic task (Howat & Wilson, 2014). In bone marrow aspirate cytology, guidance describes methanol-fixed smears with Romanowsky staining as standard practice (Lee et al., 2008). Honey has been proposed as a preservative because of its concentrated sugars, acidity, and other physicochemical properties. These proposed mechanisms do not by themselves demonstrate adequate fixation; suitability must be established through specimen-specific assessment.

For this study, honey concentration was the independent variable (50%, 70%, and 100%). The dependent outcomes were assessor ratings of nuclear detail, cytoplasmic detail, cell morphology, staining quality, and background clarity, with an overall score derived from these domains. Fixation duration, staining procedure, and blinded assessment were intended to be held consistent. This framework treats each score as a measure of observed cytomorphological quality, not as proof of diagnostic accuracy or equivalence to methanol.

2.2 Empirical Review

Studies of honey in cytology have produced encouraging but specimen-specific findings. Singh et al. (2015) compared 20% unprocessed honey with ethanol in oral smears from 30 participants. Adequate fixation was reported for 80% of honey-fixed and 90% of ethanol-fixed smears; the difference was not statistically significant. Priyadarshi et al. (2022) compared 20% honey with 95% ethanol in 300 samples from body fluids, cervical smears, and fine-needle aspiration material and reported comparable morphology and strong agreement. These studies support further evaluation but do not address graded honey concentrations in marrow smears. Ishaq et al. (2017) compared honey with alcohol in fine-needle aspiration cytology. In tissue studies, Lalwani et al. (2015) evaluated processed and unprocessed honey in oral tissue, while Sabarinath et al. (2014) compared honey with formalin in oral and maxillofacial tissue specimens. Alwahaibi et al. (2023) examined neutral honey and other honey preparations in histopathology. These studies suggest that honey can preserve some tissue and cytological features under particular protocols, but they do not establish performance in bone marrow aspirate smears.

For conventional cytological fixation, Kumarasinghe et al. (1997) compared methanol with ethanol in 108 thyroid fine-needle aspiration samples and found similar preservation scores. This supports methanol as a relevant comparator for cytological work, although it was not included in the present study. Gajendra et al. (2015) evaluated Leishman and Giemsa staining in blood and bone marrow smears, illustrating the importance of stain performance for nuclear and cytoplasmic assessment. Their study addressed staining rather than honey fixation. Taken together, prior work leaves a specimen-specific gap: it does not establish whether 50%, 70%, or 100% honey preserves bone marrow aspirate cytomorphology. The reviewed empirical studies support investigating honey as a possible fixative but vary

© 2026 Author(s). This article is licensed under the Creative Commons Attribution–NonCommercial 4.0 International License (CC BY-NC 4.0)

substantially in specimen type, concentration, comparator, and scoring system. None establishes whether graded honey concentrations preserve bone marrow aspirate cytomorphology. This study addresses that specimen-specific gap by comparing descriptive ratings across three concentrations at a Kenyan tertiary laboratory. Its findings remain preliminary because the analysis is descriptive and lacks a conventional-fixative comparator.

III. METHODOLOGY

3.1 Research Design

A laboratory-based comparative experimental design was used to assess smear morphology after fixation with three honey concentrations. This design was suitable for the stated objective because it allowed the fixation condition to be varied under laboratory conditions while the staining and assessment procedures were standardized. The study compared cytomorphological ratings across honey concentrations; it did not test diagnostic accuracy or equivalence against a conventional fixative.

3.2 Study Area

The study was conducted at the Histopathology Laboratory of Moi Teaching and Referral Hospital (MTRH)/AMPATH in Eldoret, Uasin Gishu County, Kenya. The laboratory was selected because it was the site where routine diagnostic bone marrow aspirate material was processed and where fixation and microscopic assessment could be conducted.

3.3 Target Population and Study Material

The target population comprised bone marrow aspirate specimens submitted for routine diagnostic evaluation at MTRH/AMPATH. The study material consisted of residual aspirate material from routine procedures; no additional aspiration was performed for research. Material was eligible when it met the protocol requirements for sufficient cellularity and acceptable preparation and storage. Specimens failing the quality criteria were excluded.

3.4 Sampling Procedure and Sample Size

Purposive sampling was used to select eligible residual specimens. The protocol planned 103 specimens; four did not meet the stated quality criteria, leaving 99 in the final analytical dataset.

3.5 Data Collection and Laboratory Procedures

Commercial unprocessed honey purchased in Baringo County was used. The 100% preparation was undiluted. The 70% and 50% preparations were made by mixing 70 mL or 50 mL of honey, respectively, with distilled water to a final volume of 100 mL. Preparations were mixed thoroughly and used fresh; a hydrometer was used to check solution density.

Additional smears were prepared from routine aspirate material and fixed for 15 minutes at room temperature in one of the three honey preparations. Slides were rinsed with distilled water to remove excess honey and air-dried. All smears were stained using May–Grünwald–Giemsa: May–Grünwald stain was applied for five minutes, followed by diluted Giemsa prepared in phosphate buffer at pH 6.8 for 15–20 minutes. Slides were gently rinsed with buffered distilled water, drained, and air-dried vertically before examination.

3.6 Cytomorphological Assessment

Two pathologists independently assessed coded slides while blinded to fixation condition. They rated nuclear detail, cytoplasmic detail, cell morphology, staining quality, and background clarity on a five-point scale: 0 = poor, 1 = fair, 2 = good, 3 = very good, and 4 = excellent. Where scoring discrepancies occurred, consensus review was used. The overall score was calculated as the average of the assessed characteristics.

3.7 Data Analysis

Data were entered in Microsoft Excel 365 and analysed using IBM SPSS Statistics version 26.0. Means and standard deviations summarized domain and overall scores by honey concentration; percentages summarized nuclear adequacy. The analysis focused on descriptive patterns across the three concentrations.

3.8 Ethical Considerations

Ethical approval was reported from the Moi Teaching and Referral Hospital/Moi University Institutional Research and Ethics Committee (IREC-MU), approval number IREC/1213/2025. A research permit was reported from the National Commission for Science, Technology and Innovation (NACOSTI), permit number NACOSTI/P/25/4179931. Specimens were assigned study numbers, and patient identifiers were not used during analysis. Study data were maintained in password-protected files accessible to the research team.

© 2026 Author(s). This article is licensed under the Creative Commons Attribution–NonCommercial 4.0 International License (CC BY-NC 4.0)

IV. FINDINGS & DISCUSSION

4.1 Overall Cytomorphological Scores

The overall mean score was highest for 100% honey (2.3, SD 0.48), followed by 70% honey (2.1, SD 0.52) and 50% honey (1.9, SD 0.59). Scores were moderate on the reported 0–4 scale and declined descriptively as honey concentration decreased. Table 1 summarizes the overall and domain scores. The difference between the highest and lowest overall means was 0.4 points on the reported 0–4 scale. The mean was 0.2 points higher at 100% than at 70% honey and another 0.2 points higher at 70% than at 50%. This regular spacing describes the observed ordering; it does not show that the concentrations differ statistically or that concentration alone caused the differences. The standard deviations, which ranged from 0.48 to 0.59 for the overall score, also show that individual ratings varied around each group mean. A mean therefore summarizes the center of the ratings but does not describe every slide or the degree to which individual preparations overlapped.

Table 1

Cytomorphological assessment scores by honey concentration

Assessment domain	100% honey, Mean (SD)	70% honey, Mean (SD)	50% honey, Mean (SD)
Nuclear detail	2.3 (0.48)	2.1 (0.52)	1.9 (0.58)
Cytoplasmic detail	2.2 (0.50)	2.0 (0.55)	1.8 (0.60)
Cell morphology	2.2 (0.49)	2.0 (0.54)	1.8 (0.62)
Staining quality	2.4 (0.46)	2.2 (0.50)	2.0 (0.55)
Background clarity	2.3 (0.47)	2.1 (0.53)	1.9 (0.58)
Overall score	2.3 (0.48)	2.1 (0.52)	1.9 (0.59)

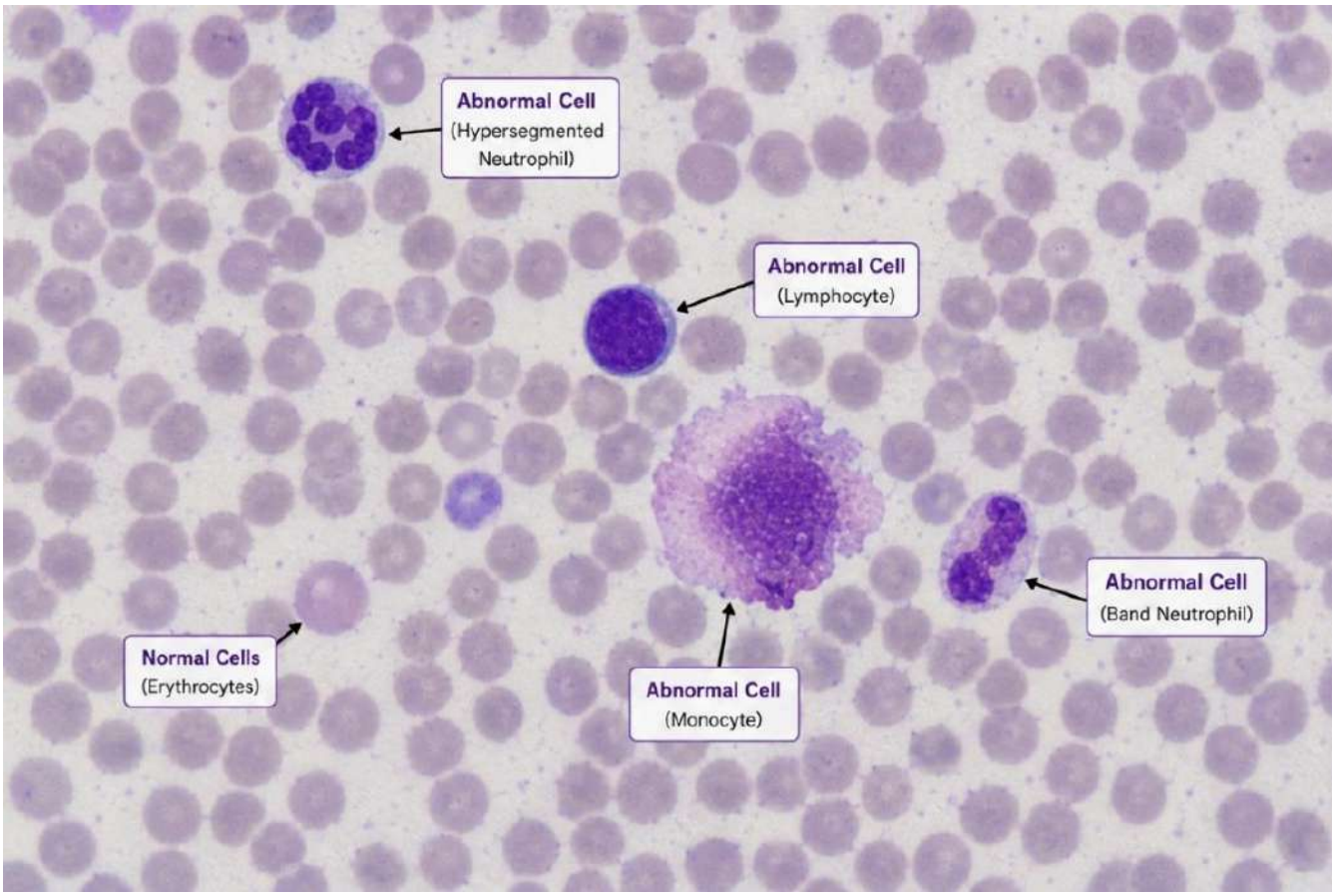

Plate 1

Representative bone marrow aspirate smear fixed with 50% honey (oil immersion, ×100).

© 2026 Author(s). This article is licensed under the Creative Commons Attribution–NonCommercial 4.0 International License (CC BY-NC 4.0)

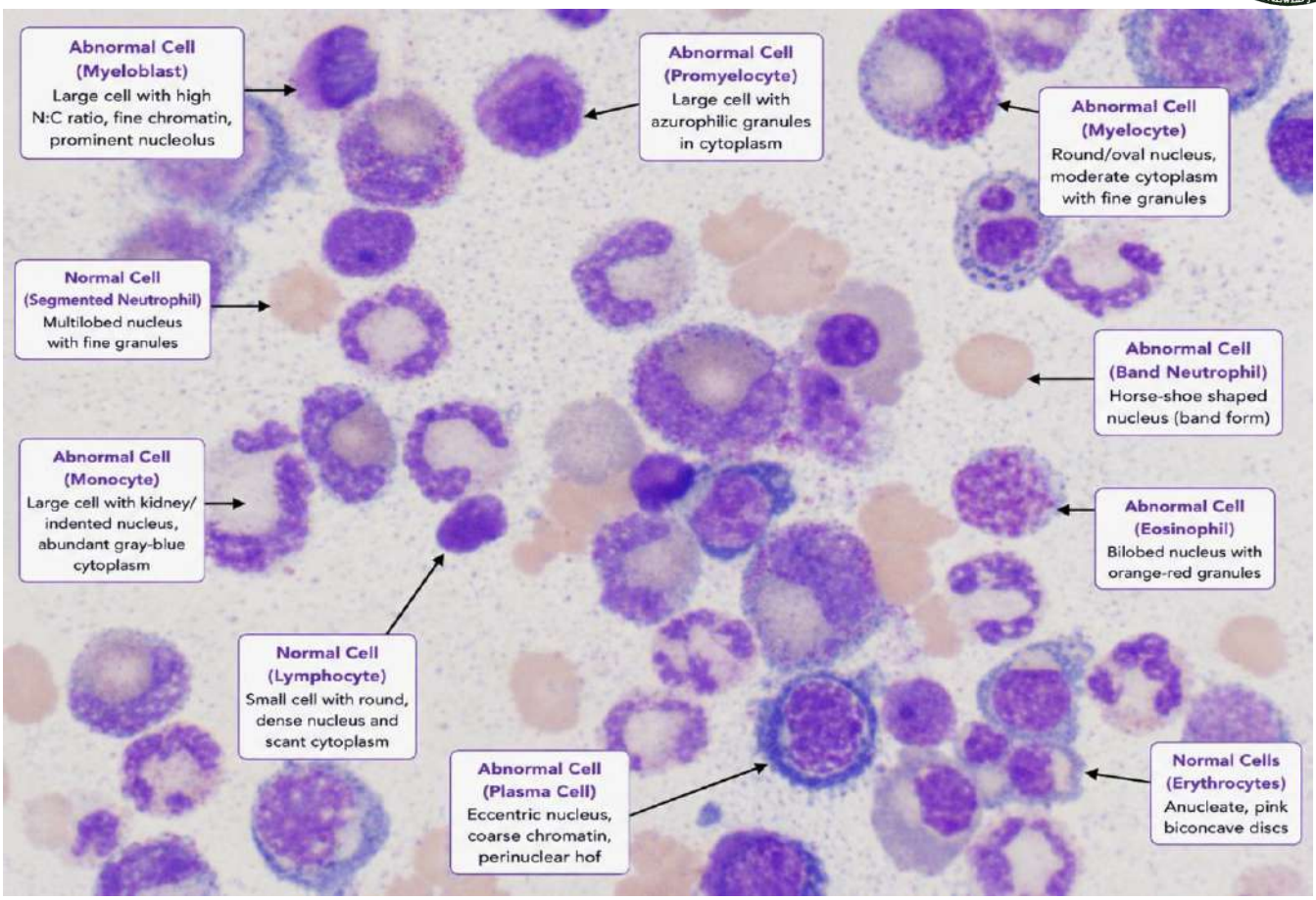

Plate 2

Representative bone marrow aspirate smear fixed with 70% honey (oil immersion, ×100).

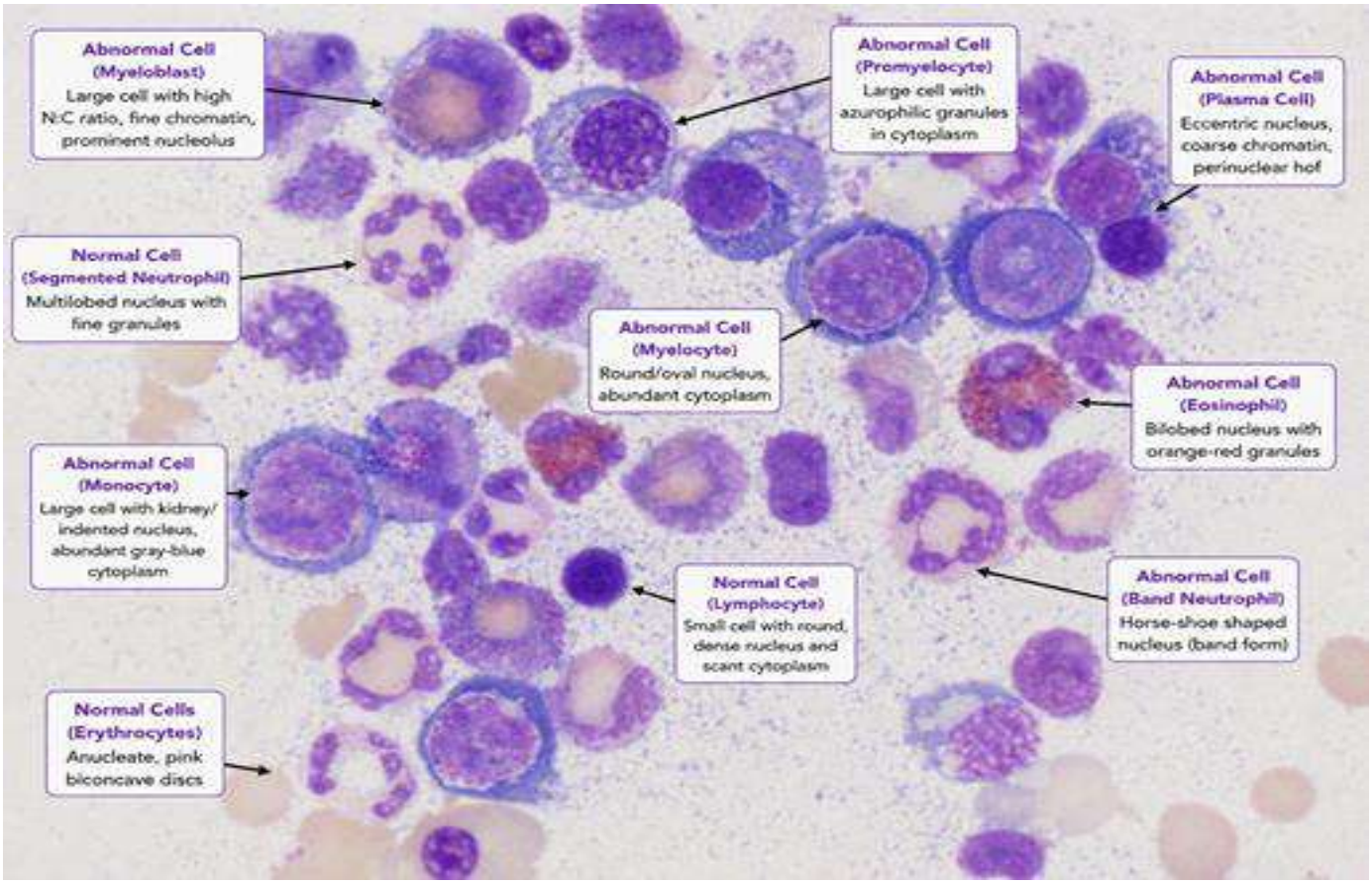

Plate 3

Representative bone marrow aspirate smear fixed with 100% honey (oil immersion, ×100).

© 2026 Author(s). This article is licensed under the Creative Commons Attribution–NonCommercial 4.0 International License (CC BY-NC 4.0)

Representative photomicrographs of smears fixed with the three honey concentrations are shown in Plates 1–3.

4.1.1 Nuclear and Cytoplasmic Detail

Nuclear-detail scores were 2.3 (SD 0.48), 2.1 (SD 0.52), and 1.9 (SD 0.58) for 100%, 70%, and 50% honey, respectively. Cytoplasmic-detail scores were 2.2 (SD 0.50), 2.0 (SD 0.55), and 1.8 (SD 0.60), respectively. Both domains showed a descending descriptive pattern as concentration decreased. For nuclear and cytoplasmic detail, the reported means differed by 0.2 points between each adjacent concentration and by 0.4 points between 100% and 50% honey. The standard deviations were 0.48, 0.52, and 0.58 for nuclear detail and 0.50, 0.55, and 0.60 for cytoplasmic detail, moving upward as the concentration decreased. These figures describe the spread of assessor ratings in the dataset. They do not identify why the ratings varied, and without the underlying score distributions or inferential analysis, they cannot establish whether the observed differences exceed ordinary variation between slides or assessors.

4.1.2 Cell Morphology, Staining Quality, and Background Clarity

Cell-morphology scores were 2.2 (SD 0.49), 2.0 (SD 0.54), and 1.8 (SD 0.62) for 100%, 70%, and 50% honey, respectively. Staining-quality scores were 2.4 (SD 0.46), 2.2 (SD 0.50), and 2.0 (SD 0.55); staining quality was the highest-rated domain at each concentration. Background-clarity scores were 2.3 (SD 0.47), 2.1 (SD 0.53), and 1.9 (SD 0.58), respectively.

Staining quality had the highest mean in each preparation: 2.4 for 100% honey, 2.2 for 70%, and 2.0 for 50%. The other domain means were close to the overall mean at each concentration. At 100% honey, for example, staining quality was 0.1 points above the overall mean, while cytoplasmic detail was 0.1 points below it. At 50%, staining quality was 0.1 points above the overall mean and cytoplasmic detail was 0.1 points below. These small differences suggest that the overall ranking was not driven by a single domain alone; however, separate domain means should be read as descriptive summaries rather than as independent evidence of diagnostic performance.

4.1.3 Reported Nuclear Adequacy

Reported nuclear adequacy was 83.8% for 100% honey, 78.8% for 70% honey, and 72.7% for 50% honey. The percentages followed the same descending pattern as the cytomorphological scores.

The reported adequacy percentage was 5.0 percentage points higher at 100% than at 70% honey, 6.1 points higher at 70% than at 50%, and 11.1 points higher at 100% than at 50%. This ordering is consistent with the ranking of the morphology scores. The manuscript reports percentages but does not provide the adequacy threshold, group denominators, or a statistical comparison alongside them. The values therefore show how adequacy was reported for the three preparations, but they cannot by themselves establish the precision of the percentages, the clinical acceptability of any preparation, or the likelihood that an individual smear would support a diagnosis.

4.2 Discussion

Across all five scored domains and the overall score, 100% honey received the highest mean ratings and 50% honey the lowest. This is a descriptive concentration-associated pattern; the analysis reported here does not establish statistical significance or causality. The moderate means also indicate that the highest-performing preparation was not rated near the top of the five-point scale. The findings therefore support further evaluation rather than a claim that honey is an adequate substitute for conventional fixation.

The same ordering across the overall score and the five component domains is a useful feature of the descriptive results. It makes the observed pattern easier to summarize: the 100% preparation received the highest mean in every reported domain, the 70% preparation was intermediate, and the 50% preparation received the lowest mean. The consistency of that ordering does not remove the study limitations. The assessors rated coded slides under the study protocol, and the values represent their ratings on a defined scale. They are not direct estimates of sensitivity, specificity, diagnostic agreement, or patient outcomes.

Table 2

Cytomorphological Scores and Reported Nuclear Adequacy by Honey Concentration

Honey concentration	Overall mean score (SD)	Reported nuclear adequacy
100%	2.3 (0.48)	83.8%
70%	2.1 (0.52)	78.8%
50%	1.9 (0.59)	72.7%

Comparison with Previous Studies:The present pattern is partly consistent with studies reporting that honey can preserve cytological material, but direct comparison is limited by differences in specimens and protocols. Singh et al. (2015) found 80% adequacy for 20% honey-fixed oral smears and 90% for ethanol-fixed smears, with no statistically

© 2026 Author(s). This article is licensed under the Creative Commons Attribution–NonCommercial 4.0 International License (CC BY-NC 4.0)

significant difference. Priyadarshi et al. (2022) reported comparable morphology and strong agreement between 20% honey and 95% ethanol across body fluids, cervical smears, and fine-needle aspiration samples. The present study did not include a conventional-fixative comparator, so its higher ratings at 100% honey cannot be interpreted as superiority to standard fixation.

The comparisons with earlier honey studies are therefore contextual rather than like-for-like. Singh et al. (2015) used oral smears and a 20% honey preparation, while Priyadarshi et al. (2022) assessed several specimen types using 20% honey and 95% alcohol. Their observations indicate that honey has been examined in cytological settings, but the specimen, concentration, reference fixative, staining protocol, and criteria differ from those used here. The marrow findings cannot be ranked against those studies as if they came from a common experiment. In particular, reports of comparable performance in other specimen types do not establish equivalence in marrow, where hematopoietic cell maturation and lineage assessment depend on a different set of morphological features.

Kumarasinghe et al. (1997) found similar cytological preservation with methanol and ethanol in thyroid fine-needle aspiration smears. That evidence supports the role of methanol as an established cytological comparator, but the present study did not compare honey with methanol or ethanol. Sabarinath et al. (2014), Lalwani et al. (2015), and Alwahaibi et al. (2023) evaluated honey in oral or histological tissue preparations. Their results provide context for honey fixation but cannot establish diagnostic performance in bone marrow aspirates. Gajendra et al. (2015) studied staining in blood and marrow smears, underscoring that stain performance also shapes morphology; their study did not test honey as a fixative.

The present study adds preliminary evidence for graded honey concentrations in bone marrow aspirate cytology, a specimen type not addressed by the reviewed comparative studies. The consistent ranking across domains suggests that concentration may matter under the protocol used. However, the absence of a reference fixative, inferential testing, a stated adequacy threshold, and an interobserver reliability estimate limits the strength and clinical interpretation of this observation. Differences in honey composition, dilution, fixation duration, staining, and specimen type across studies also caution against attributing variation to concentration alone.

The concentration pattern should also be interpreted in light of what the design can and cannot separate. Honey concentration varied, and the smear staining and assessment procedures were intended to be consistent. Even so, the document does not report a direct conventional-fixative control, inferential tests, a formal adequacy threshold, or an interobserver reliability statistic. Without these elements, it is not possible to determine whether the mean differences are statistically distinguishable, whether assessors applied the scale consistently, or how the honey-fixed smears compare with routine methanol-fixed slides. The absence of a reference group is especially important: the highest-rated honey preparation may still fall short of, match, or exceed a conventional preparation, and the present data do not answer that comparison.

4.2.1 Interpretation of the concentration pattern

The observed gradient is orderly across the reported outcomes: scores for 100% honey are highest, those for 70% are intermediate, and those for 50% are lowest. The difference between 100% and 50% is 0.4 points for the overall score and for each of the five component domains. This uniformity may be useful when planning a larger comparative study because it identifies a pattern worth testing under a design with a reference fixative and prespecified analysis. It should not be described as a proven dose-response relationship. The study compared three preparations and reports descriptive summaries; it does not establish a continuous relationship across all concentrations, prove a mechanism, or show that the concentration difference itself explains the rating pattern. Other features of the honey or preparation could also matter, and these were not isolated by the reported analysis.

4.2.2 Reading the domain scores together

The component scores help show which aspects of the smear received comparatively stronger ratings. Staining quality was the highest-scoring domain at each concentration, while cytoplasmic detail was the lowest. Nuclear detail, cell morphology, and background clarity occupied a similar range, and all five domains followed the same concentration ordering. This pattern suggests that the lower overall means at the diluted preparations were not confined to one reported characteristic. At the same time, the close values among domains caution against overstating small differences within a concentration. A mean of 2.4 for staining quality and 2.2 for nuclear detail at 100% honey is a numerical difference of 0.2 points; without an analysis designed to compare domains and their uncertainty, it is not evidence that one morphological feature was reliably better preserved than another. The ratings also do not indicate whether a particular cell lineage or maturation stage could be identified accurately.

4.2.3 Nuclear adequacy and diagnostic interpretation

The reported nuclear adequacy percentages reinforce the descriptive ordering of the mean scores. The largest separation, 11.1 percentage points between 100% and 50% honey, may be relevant to future study planning, but its meaning depends on how adequacy was defined and how many observations contributed to each percentage. Those

© 2026 Author(s). This article is licensed under the Creative Commons Attribution–NonCommercial 4.0 International License (CC BY-NC 4.0)

details are not supplied with the reported values. Adequacy is also not interchangeable with diagnostic accuracy: a smear could meet a morphology threshold yet still lead to disagreement in cell classification, while a smear below a broad threshold might remain interpretable in a specific context. Future work should define the adequacy criteria before slide review, report numerators and denominators, and evaluate diagnostic concordance using an appropriate comparator and blinded assessment. Until then, the percentages should be read as study-specific descriptive results.

4.2.4 Strengths and limitations of the findings

The study provides a comparison of three honey concentrations in bone marrow aspirate material from a Kenyan tertiary hospital, addressing a specimen-specific question not answered by the cited studies of oral cytology, body fluids, fine-needle aspiration, or tissue sections. It also reports five component domains alongside an overall score and describes blinded independent review by two pathologists. These features make the results useful as preliminary local evidence and provide outcomes that can inform a more rigorous validation protocol. Several limitations constrain interpretation. The analysis is descriptive and does not report statistical tests or confidence intervals. No conventional fixative was included, so the study cannot support a replacement claim. The adequacy threshold and group denominators are not stated, and no interobserver agreement estimate is reported. The sample came from one laboratory and the document does not provide the distributions of ratings or diagnostic outcomes for individual specimens. In addition, honey composition can vary by source, while the reported comparison is framed by concentration. The results therefore apply to the preparations and procedures described, and should not be generalized to all honey products, laboratories, stains, or diagnostic settings.

4.2.5 Implications for further work

The next study should test the observed pattern rather than assume it. A prespecified protocol could compare the three honey preparations with a conventional fixative on comparable smears from the same eligible specimens, with coded slides, blinded review, and standardized staining. Investigators should define the primary outcome and adequacy threshold in advance, justify sample size, report group denominators, and retain the score distributions so readers can see the range and overlap behind each mean. Agreement between assessors should be quantified, and diagnostic endpoints should address whether marrow cell populations and maturation patterns can be interpreted consistently. Recording honey source and preparation characteristics would help distinguish concentration from other possible influences. Multi-centre replication could then assess whether a result observed in this laboratory is reproducible elsewhere. These steps would provide the comparative evidence needed before considering any change to routine fixation practice.

4.2.6 Transferability to other laboratory settings

The results were generated in the Histopathology Laboratory of MTRH/AMPATH using the honey preparations, fixation duration, staining sequence, and assessment approach described in the methods. Their direct relevance is therefore strongest for understanding performance under this study protocol. Application elsewhere could be affected by differences in honey source and composition, water quality, smear thickness, fixation timing, stain preparation, microscope conditions, and local assessment practices. These are not reasons to discount the observed pattern; they are conditions that need to be documented and tested before assuming that the same scores would be obtained in another laboratory. Replication with a clearly specified protocol, followed by evaluation across sites, would help separate a reproducible concentration-related pattern from variation associated with materials or procedures. This distinction matters because a fixative that is feasible to prepare in one setting may not produce consistent results when the source material or workflow changes. The present study provides a starting point for such replication, rather than a basis for generalizing performance across institutions.

4.2.7 Meaning of the rating scale for practice

The ratings provide a structured description of how the reviewed smears appeared to the assessors on the study scale. They are useful for comparing the three preparations within this dataset, especially because the same five domains and the same scale were applied across groups. A mean score, however, compresses several observations into one number. It does not show whether a score reflects consistently similar slides or a mixture of strong and weak preparations, nor does it show which individual cellular features were decisive in a diagnostic interpretation. Standard deviations partly describe variability but cannot replace the full distribution of scores, representative slide-level observations, or a measure of agreement between assessors. Future reports should therefore pair summary means with group sizes, score distributions, explicit adequacy criteria, and representative images reviewed under consistent conditions. A separate diagnostic comparison should determine whether morphological ratings correspond to reliable identification and interpretation. Until such evidence is available, the scores should be used to guide research questions and protocol refinement, not to make clinical substitution decisions.

© 2026 Author(s). This article is licensed under the Creative Commons Attribution–NonCommercial 4.0 International License (CC BY-NC 4.0)

V. CONCLUSION & RECOMMENDATIONS

5.1 Conclusion

Among the three honey preparations assessed, 100% honey had the highest mean scores for nuclear detail, cytoplasmic detail, cell morphology, staining quality, background clarity, and overall cytomorphological assessment. Scores declined descriptively at 70% and 50%. Because scores were moderate, the analysis was descriptive, and there was no conventional-fixative comparator, the study does not establish diagnostic equivalence or readiness for routine use.

5.2 Recommendations

Further studies should use larger, preferably multi-centre samples and a prespecified sample-size rationale. They should compare standardized honey preparations with a conventional reference fixative, report group denominators and adequacy criteria, and assess interobserver agreement and diagnostic endpoints. Honey source and physicochemical characteristics, preparation, fixation duration, and staining conditions should be documented. Until comparative validation is available, honey should not be assumed to replace conventional fixatives in routine diagnostic practice. Study design and comparison. Compare standardized 50%, 70%, and 100% honey preparations directly with a conventional reference fixative, such as methanol, using adequately powered studies and a prespecified sample-size rationale. Where feasible, prepare comparable smears from the same specimens and allocate them to fixation conditions; keep staining and assessment procedures consistent. Multi-centre participation would help assess whether findings apply beyond one laboratory.

Preparation and protocol reporting. Document the honey source and relevant physicochemical characteristics, dilution method, preparation and storage conditions, fixation duration, temperature, smear preparation, and staining procedure. This will help determine whether observed differences are reproducible and attributable to the fixation protocol. Assessment and analysis. Use a prespecified scoring system with explicit definitions and adequacy thresholds for each cytomorphological domain. Report group denominators, the number of specimens and slides assessed, missing or excluded observations, and the distribution of results. Assess interobserver agreement and use appropriate statistical comparisons with uncertainty estimates.

Diagnostic validation and implementation. Evaluate diagnostic concordance and clinically relevant endpoints, including whether cell identification and marrow interpretation are maintained, before drawing conclusions about diagnostic use. If performance is supported, further assess preparation stability, practical handling, and feasibility in the intended laboratory setting. Current practice. Until comparative validation demonstrates acceptable performance for the intended diagnostic task, honey should be treated as investigational and should not be assumed to replace conventional fixatives in routine diagnostic practice.

Declaration of Interest

The authors declare that they do not have any known competing financial interests or personal relationships that could have appeared to influence the work reported in this paper.

Funding Declaration

This research did not receive any specific grant from funding agencies in the public, commercial, or not-for-profit sectors.

REFERENCES

Alwahaibi, N., Al Dhahli, B., Al Issaei, H., Al Wahaibi, L., & Al Sinawi, S. (2023). Effectiveness of neutral honey as a tissue fixative in histopathology. *F1000Research, 11*, 1014. https://doi.org/10.12688/f1000research.122598.3

Gajendra, S., Jha, B., Goel, S., Sahni, T., Sharma, R., Shariq, M., Jaiswal, S., & Sachdev, R. (2015). Leishman and Giemsa stain: A new reliable staining technique for blood/bone marrow smears. *International Journal of Laboratory Hematology, 37*(6), 774–782. https://doi.org/10.1111/ijlh.12408

Howat, W. J., & Wilson, B. A. (2014). Tissue fixation and the effect of molecular fixatives on downstream staining procedures. *Methods, 70*(1), 12–19. https://doi.org/10.1016/j.ymeth.2014.01.022

Ishaq, R., Azmat, H., Omair, M., Sheikh, A. K., & Tanwani, A. K. (2017). Comparison of honey with alcohol as a fixative in fine needle aspiration cytology. *International Journal of Pathology, 15*(1), 15–18. https://jpathology.com/index.php/OJS/article/view/269

Kumarasinghe, M. P., Constantine, S. R., & Hemamali, R. L. (1997). Methanol as an alternative fixative for cytological smears. *Malaysian Journal of Pathology, 19*(2), 137–140. https://pubmed.ncbi.nlm.nih.gov/10879255/

© 2026 Author(s). This article is licensed under the Creative Commons Attribution–NonCommercial 4.0 International License (CC BY-NC 4.0)

Lalwani, V., Surekha, R., Vanishree, M., Koneru, A., Hunasgi, S., & Ravikumar, S. (2015). Honey as an alternative fixative for oral tissue: An evaluation of processed and unprocessed honey. *Journal of Oral and Maxillofacial Pathology, 19*(3), 342–347. https://doi.org/10.4103/0973-029X.174641

Lee, S.-H., Erber, W. N., Porwit, A., Tomonaga, M., & Peterson, L. C. (2008). ICSH guidelines for the standardization of bone marrow specimens and reports. *International Journal of Laboratory Hematology, 30*(5), 349–364. https://doi.org/10.1111/j.1751-553X.2008.01100.x

Priyadarshi, A., Kaur, R., & Issacs, R. (2022). Honey as a cytological fixative: A comparative study with 95% alcohol. *Cureus, 14*(8), Article e28149. https://doi.org/10.7759/cureus.28149

Sabarinath, B., Sivapathasundharam, B., & Sathyakumar, M. (2014). Fixative properties of honey in comparison with formalin. *Journal of Histotechnology, 37*(1), 21–25. https://doi.org/10.1179/2046023613Y.0000000037

Singh, A., Hunasgi, S., Koneru, A., Vanishree, M., Ramalu, S., & Manvikar, V. (2015). Comparison of honey with ethanol as an oral cytological fixative: A pilot study. *Journal of Cytology, 32*, 113–117. https://doi.org/10.4103/0970-9371.160563

World Health Organization. (1997). *Methanol: Health and safety guide* (Health and safety guide no. 105). https://iris.who.int/bitstream/handle/10665/41944/9241511052_eng.pdf

© 2026 Author(s). This article is licensed under the Creative Commons Attribution–NonCommercial 4.0 International License (CC BY-NC 4.0)